

Case reports from a monocentric pilot study

# Functional Evaluation of Screw Implants in Combination with Reduced-diameter Abutments

Dr Ralf Masur, Dr Andreas Kraus and Jan Märkle, Bad Wörishofen/Germany

Since the summer of 2008, our implant centre has been conducting a monocentric pilot study to evaluate the function of Camlog Screw-Line K series implants. The most important innovation this product offers is the possibility to use reduced-diameter impression posts, healing caps and abutments ("platform switching"). The main objective of this study is to determine at which height the bone level can be retained relative to the implant shoulder. To this end, the study examines maxillary anterior (14 to 24) single-tooth gaps over the study period of twelve months. Additional objectives are the evaluation of the aesthetic results and patient satisfaction during this period and to follow the restored implants over 18, 24, 36, 48 and 60 months.

Today's enossal implants osseointegrate reliably. Implant-supported dentures, fixed or removable, restore the patients' masticatory function. Clinical longitudinal studies have shown that these restorations can be stable over a period of 20 years or more [1].

In recent years, aesthetic considerations related to implant-based rehabilitations have increasingly gained weight in addition to the aspects of osseointegration and the restoration of function.

Placing implants in the aesthetic zone is a highly technique-sensitive procedure. But in addition to the surgeon's skills, the design of the implant and the prosthetic components also play an important role for the final aesthetic outcome [2, 3].

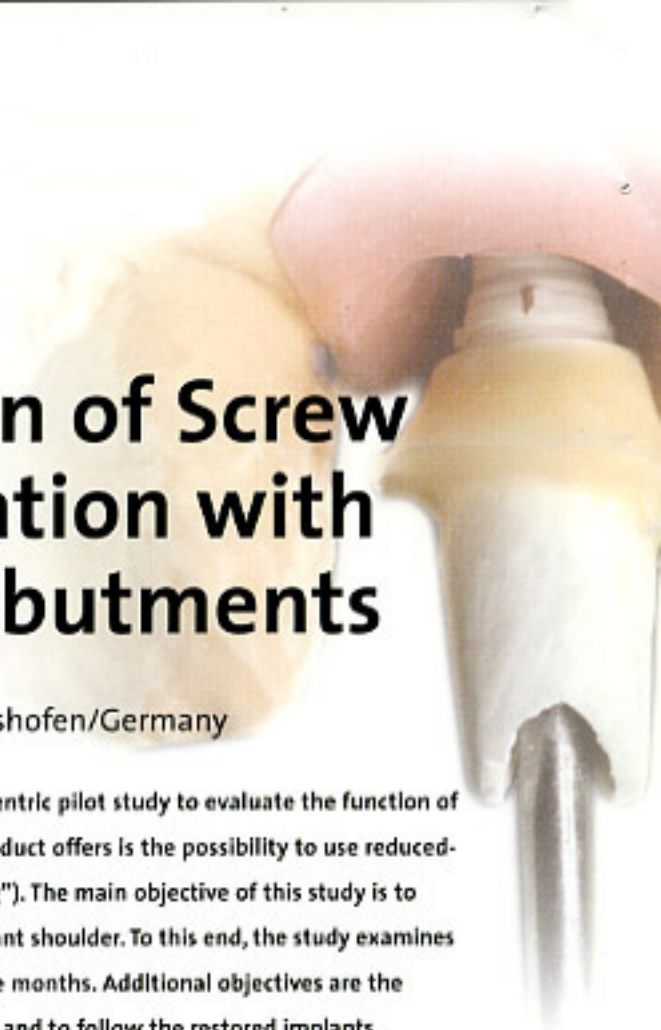These factors have an influence on the peri-implant bone, whose height and thickness determines the stability of the peri-implant soft tissues and, hence, the aesthetic result. From the moment of first contact between the implant and the oral cavity, bone loss will ensue (and be visible radiologically), if the implant was placed subcrestally rather than transgingivally. Some authors believe that the bone loss is caused by mechanical loads [7, 8], while others believe the cause to be local inflammation of the peri-implant soft tissues, which in turn is caused by bacterial infiltration of the microgap at the implant-abutment interface [9]. That the latter explanation is the more probable one is also demonstrated by Ericsson

*et al.* [10, 11], who found an inflammatory connective-tissue infiltrate at this interface. The infiltrate itself is never in direct contact with the bone, but remains separated from it by a layer of healthy connective tissue approximately 1 mm in thickness.

Several authors have reported that the use of abutments with a reduced diameter compared to the implant improves the stability of the peri-implant bone. However, most of the relevant studies have the status of case reports [13, 14].

Many longitudinal studies have been published that examine implant survival rates, but reports on the stability of soft and hard tissues cover only short observation periods. The objective of our study is to examine radiological changes in bone levels and the stability of the soft tissues and, hence, red/white aesthetics. An additional objective is to assess patient satisfaction up to twelve months following implant placement and at 18, 24, 36, 48 and 60 months. This monocentric study is intended to be the basis for larger multicentre studies. The study design and timeline can be seen in Figure 1.

The Camlog Screw-Line K series implants are available in the familiar diameters and lengths (diameters: 3.3, 3.8, 4.3, 5.0, 6.0 mm; lengths: 9 (except 3.3 mm diameter), 11, 13, 16 mm). The present study only looks at implants 3.8, 4.3 and 5.0 mm in diameter and 9, 11 and 13 mm in length. The diameter of Camlog abut-



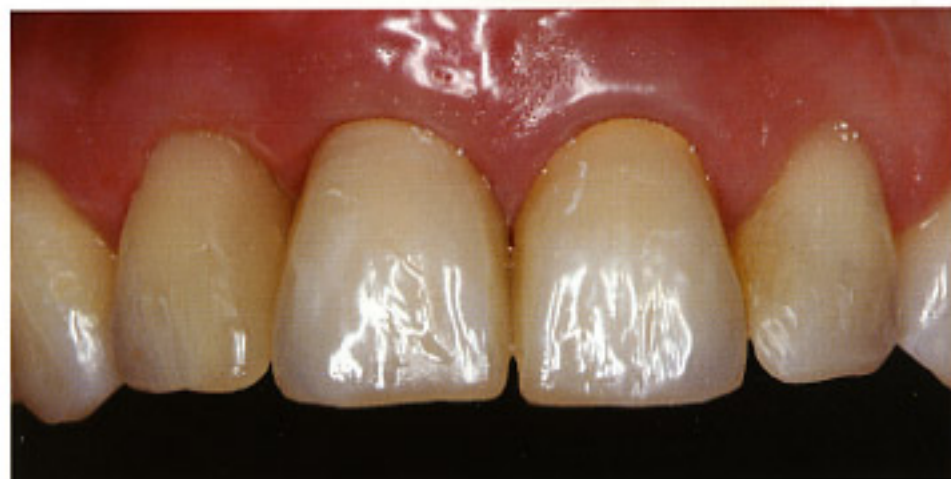
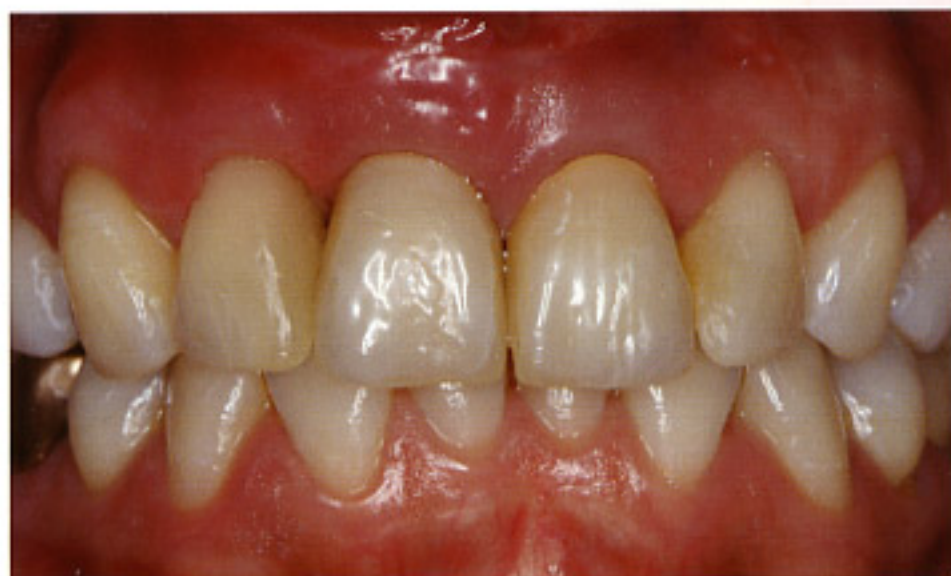
Fig. 33  
Stable autologous  
bone contour  
following extensive  
augmentation.

Fig. 34  
Surgically optimized  
harmonious gingival  
line of provisional  
crowns 21 and 22.

According to a study by Lazzara and Porter [13], the amount of bone resorption at the implant shoulder can be reduced by using secondary prosthetic components whose diameter is smaller than that of the implant shoulder. This phenomenon has been explained by the reduced space available for an inflammable infiltrate at the implant-abutment interface. The greater distance between microgap and bone and their horizontal relocation have an additional positive effect [13].

The study on which we have been reporting here is still in progress. Its objective is to further evaluate the effects of platform switching. The study is supported by the camlog foundation.

### Acknowledgments

We would like to thank *Stefan Plecha* (master dental technician, Fürth) for the laboratory work in the first case and *Ralf Bahle* (master dental technician, Leutkirch) for the laboratory work in the second case. We would also like to thank *Martina Pause* (dentist, Bad Wurzach) for the execution of the prosthetic work in the second case. ■

### Contact Address

Implantzentrum Bad Wörishofen,  
Unterschleißheim & Kochel  
Dr Ralf Masur · Dr Andreas Kraus · Jan Märkle & Kollegen  
Kneippstrasse 12 · 86825 Bad Wörishofen · GERMANY  
Phone: +49 8247 99830-0  
info@implantissimo.de · www.implantissimo.de



## References

- [1] Ekelund JA, Lindquist LV, Carlsson GE, Jemt T: Implant treatment in the edentulous mandible. A prospective study on Branemark system implants over more than 20 years; *Int J Prosthodont* 2003; 16(6): 602-608.
- [2] Canullo L, Rasperini G: Preservation of peri-implant soft and hard tissues using platform switching of implants placed in immediate extraction sockets: a proof-of-concept study with 12- to 36-month follow-up; *Int J Maxillofac Implants* 2007; 22: 995-1000.
- [3] Belser UC, Schmid B, Higginbottom F, Buser D: Outcome analysis of implant restorations located in the anterior maxilla: A review of the recent literature; *Int J Oral Maxillofac Implants* 2004; 19 (suppl): 30-42.
- [4] Hermann JS, Buser D, Schenk RK, Schoolfield JD, Cochran DL: Biologic width around one- and two-piece titanium implants; *Clin Oral Implants Res* 2001; 12: 559-571.
- [5] Hartman GA, Cochran DL: Initial implant position determines the magnitude of crestal bone remodelling; *J Periodontol* 2004; 75: 572-577.
- [6] Fischer K, Senberg T: Early loading of ITI implants supporting a maxillary full-arch prosthesis: 1-year data of a prospective, randomized study; *Int J Maxillofac Implants* 2004; 19: 374-381.
- [7] Pilliar RM, Deporter DA, Watson PA, Valiquette N: Dental implant design: Effect on bone remodelling; *J Biomed Mater Res* 1995; 25: 467-483.
- [8] Kitamura E, Stegarou R, Nomura S, Miyakawa O: Biomechanical aspects of marginal bone resorption around osseointegrated implants: Considerations based on a three-dimensional finite element analysis; *Clin Oral Implants Res* 2004; 15: 401-412.
- [9] Jansen JA, Conrads G, Richter EJ: Microbial leakage and marginal fit of the implant-abutment interface; *Int J Oral Maxillofac Implants* 1997; 12: 527-540.
- [10] Ericsson I, Berglundh T, Manniello CP, Ljkenberg B, Lindhe J: Long-standing plaque and gingivitis at implants and teeth in the dog; *Clin Oral Implants Res* 1992; 3: 99-103.
- [11] Ericsson I, Persson LG, Berglundh T, Manniello CP, Lindhe J, Klinge B: Different types of inflammatory reactions in periimplant soft tissues; *J Clin Periodontol* 1995; 22: 255-261.
- [12] Lazzara RJ, Porter SS: Platform switching: A new concept in implant dentistry for controlling postrestorative crestal bone level; *Int J Periodontics Restorative Dent* 2006; 26: 9-17.
- [13] Canullo L, Rasperini G: Preservation of peri-implant soft and hard tissues using platform switching of implants placed in immediate extraction sockets: A proof-of-concept study with 12- to 36-month follow-up; *Int J Maxillofac Implants* 2007; 22: 995-1000.
- [14] Tarnow DP, Magner AW, Fletcher P: The effect of the distance from the contact point to the crest of bone on the presence or absence of the interproximal dental papilla; *J Periodontol* 1992; 63: 995-996.

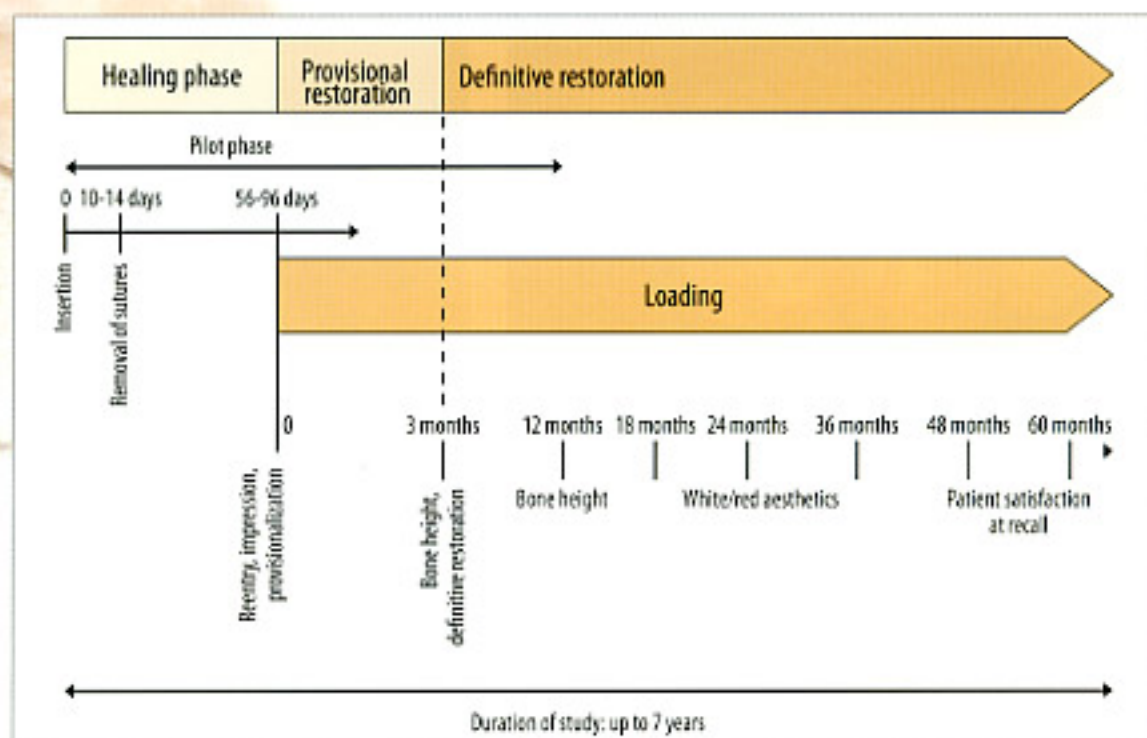


Fig. 1  
Study design.

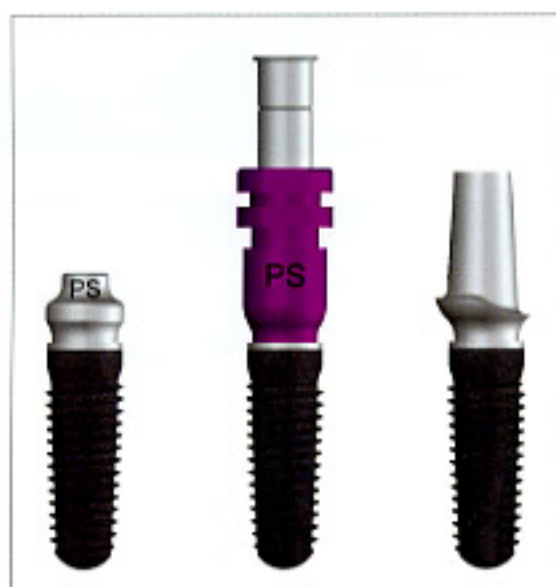

Fig. 2  
Platform  
switching:  
Screw-Line K  
series implant  
with bottleneck  
PS healing cap,  
impression post  
PS for open-tray  
impressions and  
Esthomic PS  
abutment.

ments with the designation PS (as in platform switching) is reduced by 0.3 to 0.5 mm relative to and depending on the implant diameter. Figure 2 shows a Camlog Screw-Line K series implant with reduced-diameter bottleneck healing cap, impression posts and straight Esthomic abutment.

Male and female patients over 18 years were included in the study if they had one or several teeth missing in the anterior aesthetic zone (teeth 14 to 24), on condition that they had a single-tooth gap bilaterally delimited by natural teeth. The antagonists had to be either natural teeth or a fixed implant-supported restoration. Implants could not be placed sooner

than six weeks following extraction; immediate-placement cases are excluded. Only minor augmentation using e.g. autologous bone chips were permissible during the surgical procedure. Any preimplantational bone augmentation had to precede implant placement by at least 3.5 months. Heavy smokers (>ten cigarettes per day) as well as patients with severe systemic diseases could not be included in the study. The study was approved by the Ethics Commission (feci 08/1651); all patients were required to sign an informed-consent form.

The clinical procedure followed in this study will be exemplified by two clinical cases.



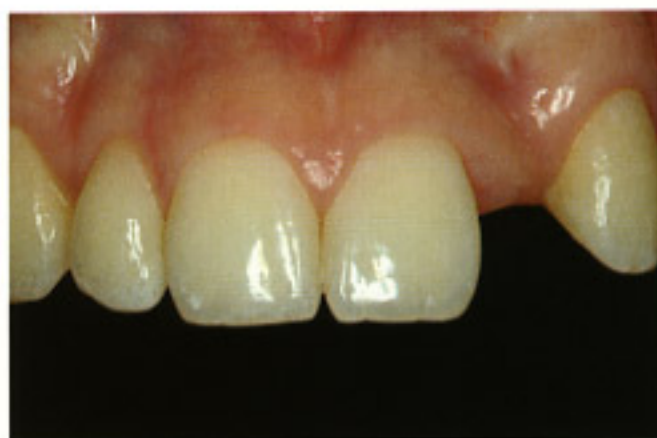

Fig. 3 18-year-old female patient. Congenitally missing tooth 22 with thin gingival biotype.

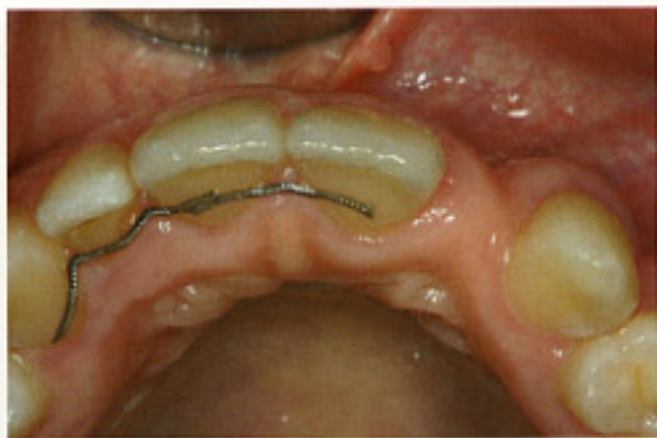

Fig. 4 Interrupted soft-tissue contours.

Fig. 5 Custom x-ray holder for taking standardized x-rays for the duration of the study.

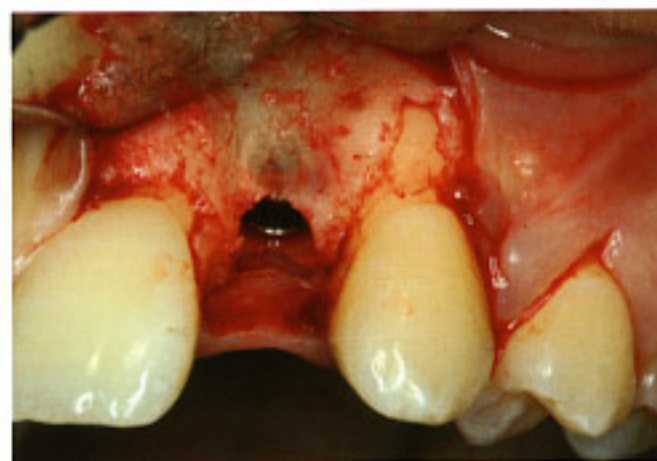



Fig. 6 Periodontal surgery to contour the bone in preparation for a natural prosthetic crown shape.

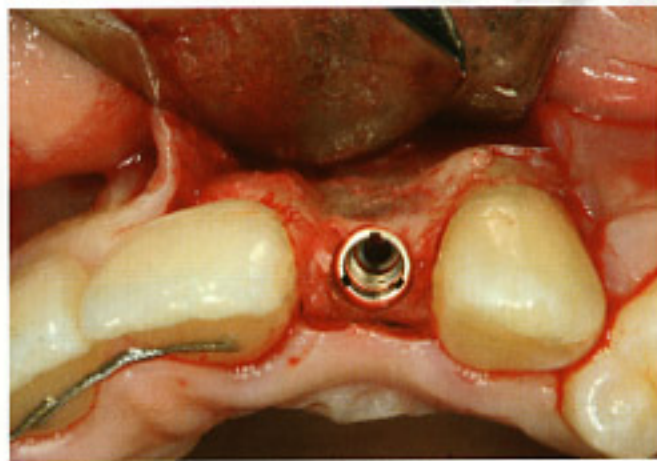


Fig. 7 Correct prosthetic alignment of the Camlog implant, with the groove facing buccally.

## Case #1

An 18-year-old woman presented at our office with a congenitally missing tooth 22 (Figs. 3 and 4).

Prior to implant placement, an x-ray holder was customized with silicone (MolloSil, Detax) and made to rest on the adjacent teeth (Fig. 5). This allowed us to take orthoradial x-rays throughout the entire study period.

A Camlog Screw-Line K series implant 3.8 mm in diameter and 13 mm in length was inserted at site 22. The sandblasted and acid-etched surface was completely covered by local bone. One of the three grooves was positioned exactly buccally (Figs. 6, and 7). The implant shoulder was placed approximately 3 mm below the cemento-enamel junction of the prospective crown. The implant was covered with the enclosed small closure screw (Fig. 8).

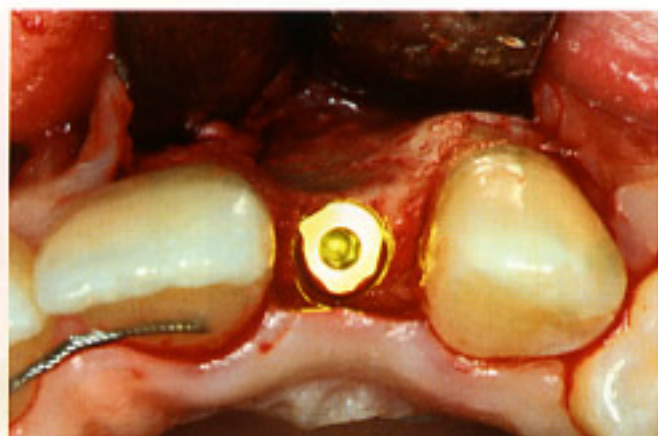


Fig. 8 Labial defect prior to the apposition of autologous bone.

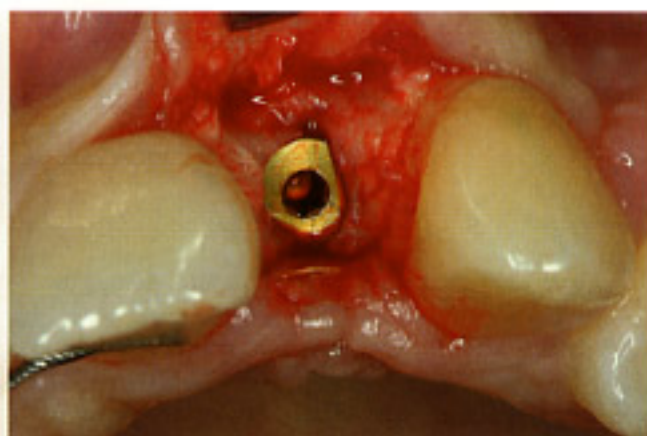


Fig. 9 Thick labial bone 3.5 months following augmentation with autologous bone and implant insertion.

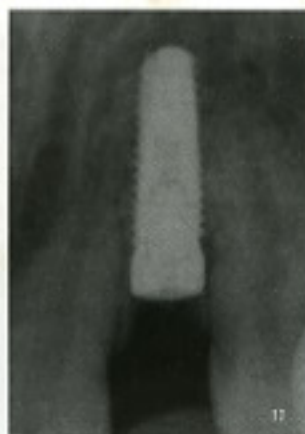
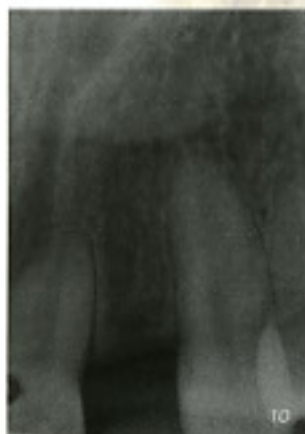
Fig. 10  
Radiograph of initial situation.

Fig. 11  
X-ray examination of the prosthetically driven implant following the rules of platform switching (see Figure 6).

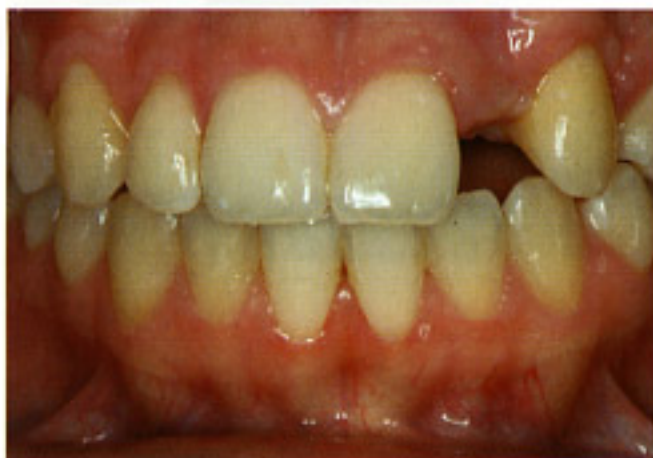

Fig. 12 Fragile gingival contour and pronounced scalloping.

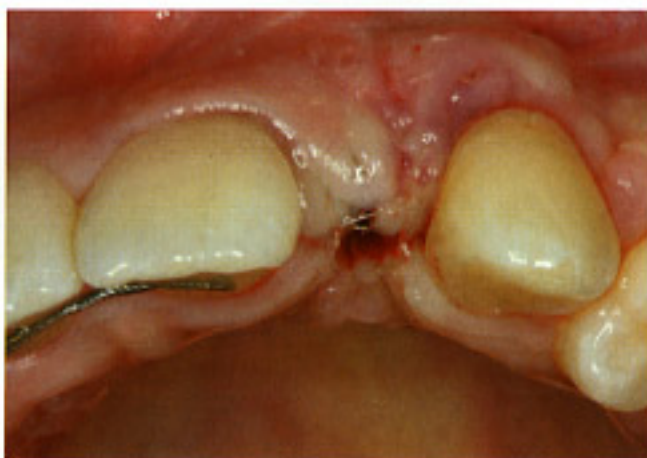

Fig. 13 Bottleneck healing cap, 4 mm in height, and semi-covered flap for increasing the gingival volume on the labial aspect.

Due to her thin buccal bone lamella, bone augmentation using autologous bone chips was simultaneously performed. The wound was closed with resorbable 4-0 and 6-0 sutures (Serapid, Serag Wiesner), taking care that the closure was tension-free and impermeable to saliva. X-rays of the surgical area were taken before and after the procedure using the custom x-ray holder (see Figs. 10 and 11).

Postoperative healing was uneventful. The postoperative control was performed ten days after the procedure.

At three months, the implant was uncovered to connect a reduced-diameter "bottleneck" healing cap 4 mm in height. The autologous bone chips that had been positioned on the buccal aspect at the time of implant placement exhibit impressive ossification (Figs. 9, 12 and 13).



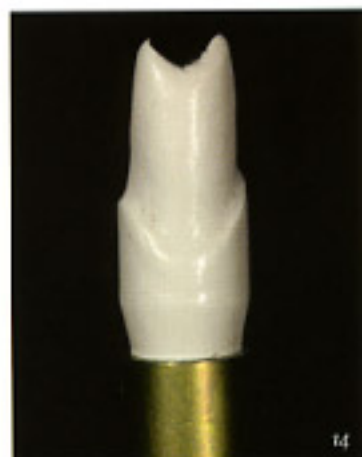

Fig. 14  
Reduced-diameter  
provisional PEEK  
abutment.

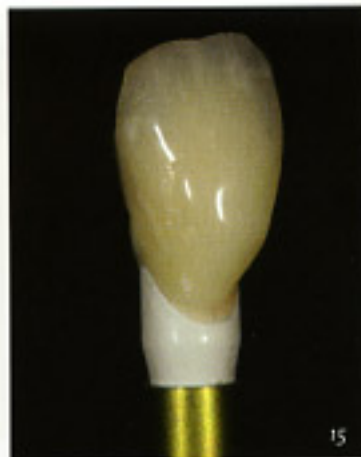

Fig. 15  
Provisional  
restoration on  
lab analogue,  
platform  
switching.

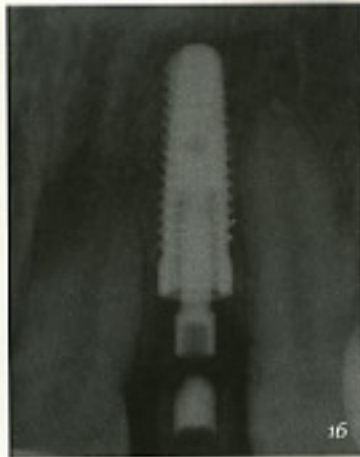

Fig. 16  
X-ray control  
after placement  
of the provisional.

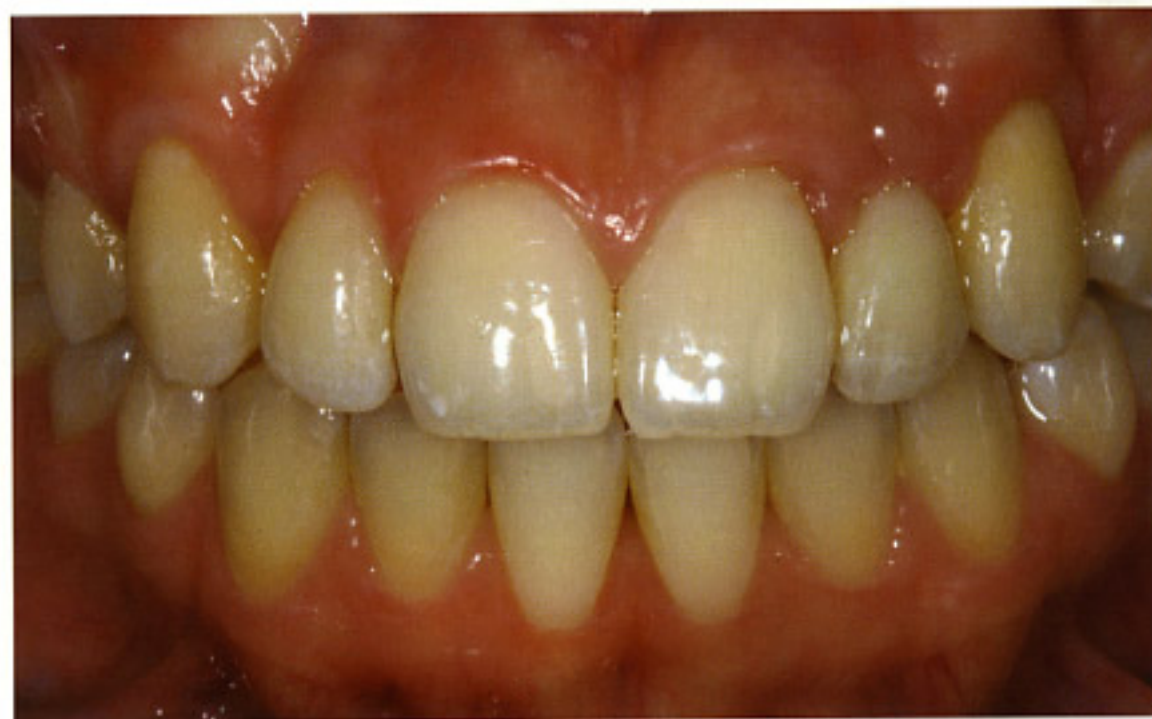

Fig. 17  
Harmonious  
gingival con-  
tours after  
placement of  
the provisional  
crown on  
tooth 22.

At two weeks after re-entry, an impression was taken for the provisional crown. To this end, the appropriate impression post for an open-tray impression was inserted, and Impregum (3M Espe) impression material was syringed around the post. The impression was taken using a custom impression tray.

At the dental laboratory, a provisional resin crown (Ivocrown, Ivoclar Vivadent) was fabricated on a reduced-diameter provisional PEEK abutment (Figs. 14 and 15).

At the dental office, the abutment was inserted into the implant and hand-tightened. The provisional crown was cemented using a eugenol-free tempo-

rary zinc oxide cement (Temp Bond, Kerr). Following cementing, a standard tooth x-ray was taken, again using the custom x-ray holder (Fig. 16).

The clinical result immediately after delivery shows harmonious gingival contours and only minor gingival irritation (Fig. 17).

After the end of the provisional phase, which took three to four months, the implant was restored with the definitive crown according to the study protocol. The patient was followed up radiologically at 12, 18, 24, 36, 48 and 60 months. In addition, the aesthetic parameters listed above were evaluated, and the patient's subjective satisfaction was assessed.

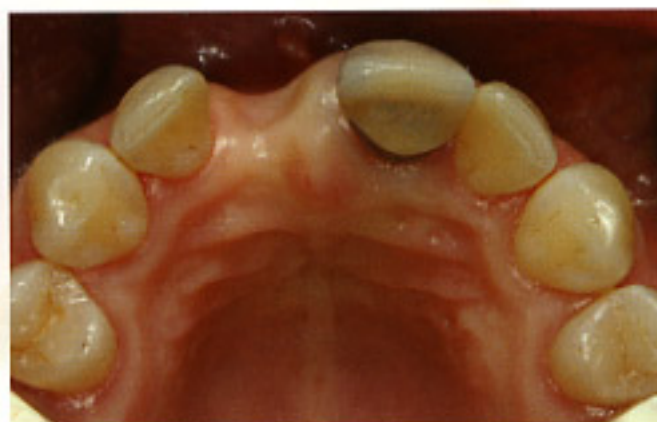

Fig. 18 Pronounced horizontal defect following the loss of tooth 11.

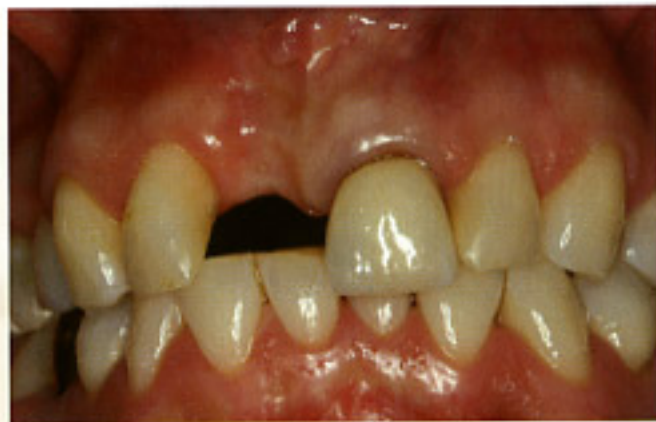

Fig. 19 Pronounced vertical loss of the soft and hard tissues labially and mesially of tooth 12, amounting to approximately 5 mm.

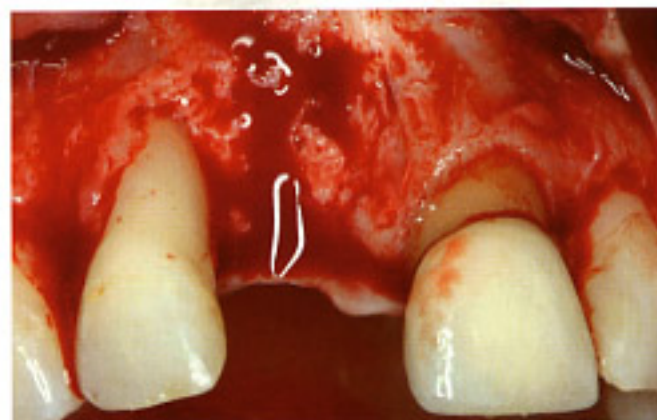


Fig. 20 Denuded defect at sites 12 and 11. Difficult baseline situation with a combined horizontal/vertical defect at the edentulous site 11 and the adjacent tooth 12.

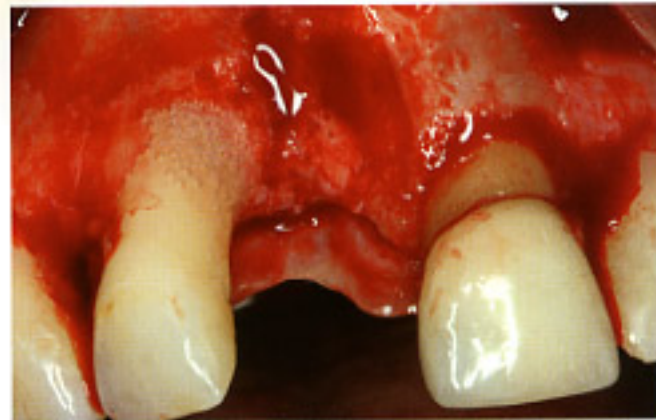


Fig. 21 Conditioning the root surface with Emdogain.

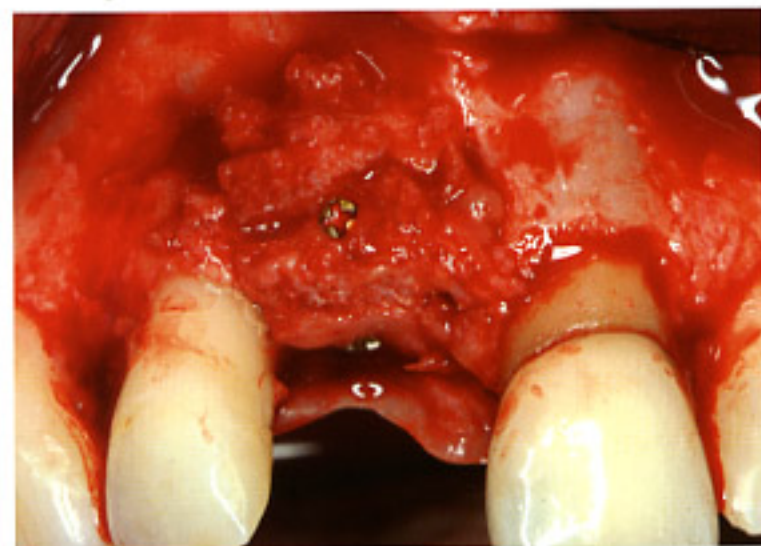


Fig. 22 3-D reconstruction, gaining approximately 5 to 6 mm by placing autologous bone blocks.

## Case #2

The second case was that of a 42-year-old woman with a single missing tooth 11 and an insufficient crown restoration of tooth 21. Tooth 11 had been lost as a consequence of a failed endodontic treatment. A massive inflammation resulted in pronounced bone destruc-

tion and, consequently, approximately 5 mm of mesial and labial bone loss around tooth 12 (Figs. 18 and 19).

This bone defect rendered a one-step procedure for aesthetic improvement impossible. In the first step, autologous bone blocks from the tuberosity regions were used to reconstruct the defect three-dimensionally. The block graft was firmly secured in place using bone-fixing screws (Medartis), and the margins were filled with cancellous bone chips.

Following careful scaling and root planing, tooth 12 was conditioned with EDTA gel (Pref Gel, Straumann), and the tooth surface was treated with Emdogain (Straumann) (Figs. 20 and 21) in order to support the wedging action of the autologous bone chips between the monoblock transplant and tooth 12 in potential subsequent bone regeneration (Fig. 22). At the same time, a connective-tissue transplant harvested from the palate was placed buccally of tooth 12 as well as on the buccal aspect of the augmentation site 11, securing it with a horizontal mattress suture. Furthermore, surgical crown lengthening was performed for tooth 21 to achieve a perfect aesthetic result. Tension-free wound closure was performed with a resorbable 4-0 suture following periosteal separation.



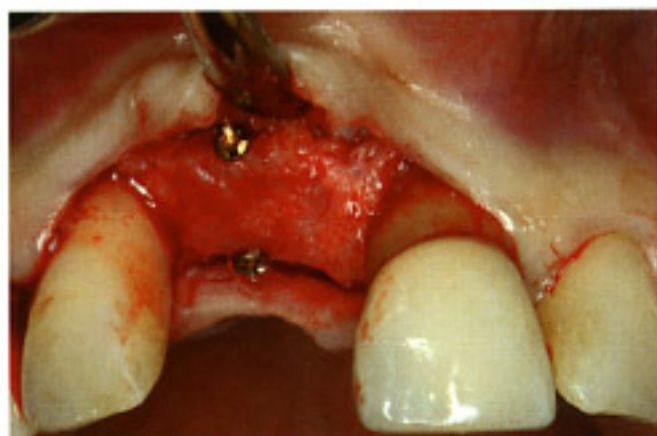


Fig. 23 Excellent bone regeneration, approximately 5 mm horizontally and vertically at the implant site and on the mesial labial aspects of tooth 12.

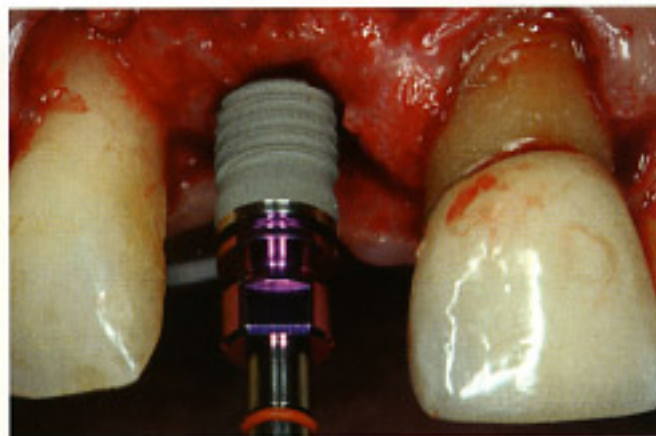


Fig. 24 Contouring the bone by periodontal surgery to optimize the prosthetic crown shape.

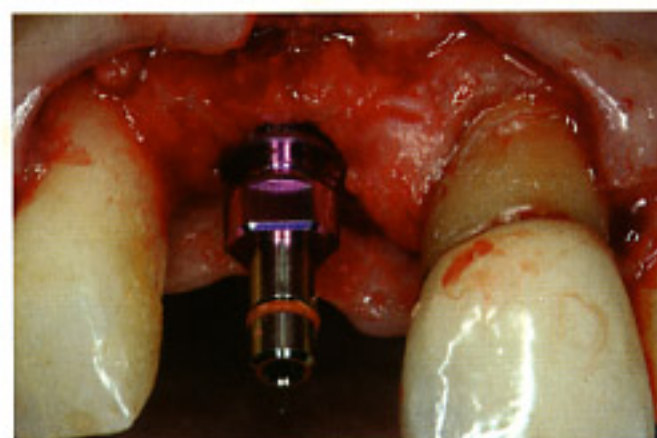

Fig. 25 Anticipating the position of the implant shoulder relative to the cemento-enamel junction of the future crown.

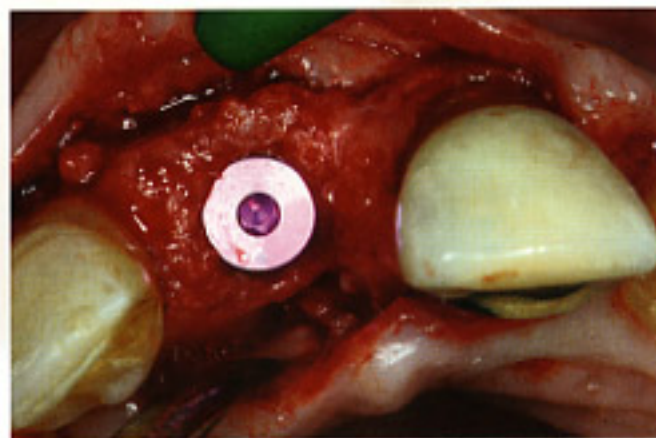


Fig. 26 More than 1.5 mm of augmented bone lamella of the buccal aspect ensure the long-term stability of the aesthetic soft-tissue situation.

The postoperative examination was performed at ten days. After 3.5 months, the second surgical step consisted of implant insertion at site 11. A Camlog Screw-Line K series implant 4.3 mm in diameter and 13 mm in length was inserted and covered with the enclosed small closure screw (Figs. 23 to 26). The wound was closed with resorbable 4-0 and 6-0 sutures, again taking care that the closure was impermeable to saliva (Fig. 27). Preoperative and postoperative standardized x-rays were taken using the custom x-ray holder.

The postoperative examination after the second step was performed at ten days. After three months, re-entry was performed by way of a crescent-shaped incision using a roll technique, and a reduced-diameter bottleneck healing cap 4 mm in height was connected (Figs. 28 to 30). At the same time, a vestibuloplasty was performed to move the mucogingival junction at site 11 apically.

Following an additional three weeks of healing and the preparation of tooth 21 for a new post-and-core, a custom impression tray and an appropriate impres-

sion post were used to take an impression of implant 11 and tooth 21 for provisionalization. Provisional crowns (Sinfonie, 3M Espe) were fabricated at the dental laboratory, on a provisional reduced-diameter PEEK abutment in the case of the implant and on a gold post-and-core in the case of tooth 21 (Figs. 31 and 32).

Following delivery of the provisional crowns, a functional build-up on the canine and a composite addition on the mesial aspect of tooth 12, the gingival contours presented harmonious and free of irritation (Figs. 33 and 34). Again, a control x-ray was taken using the custom x-ray holder.

The treatment plan calls for developing the soft tissue and shaping the gingiva by the provisional restoration according to the study published by Tarnow [15], followed by definitive restoration within the following three to four months. Within the framework of the study, radiological follow-ups are planned at 12, 18, 24, 36, 48 and 60 months, in addition to evaluating aesthetic parameters and the patient's subjective satisfaction.



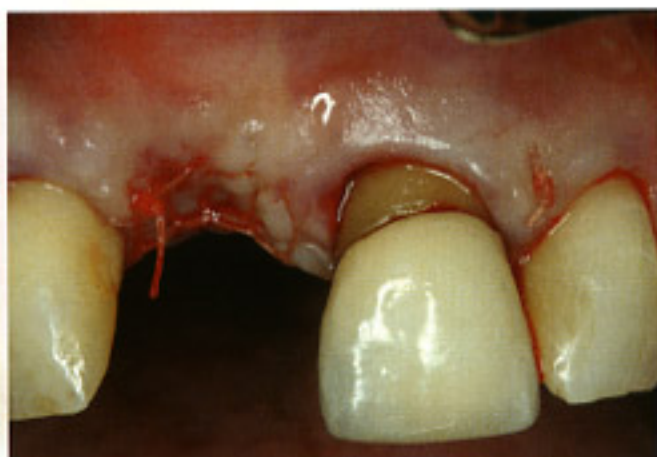


Fig. 27 Dense suture.

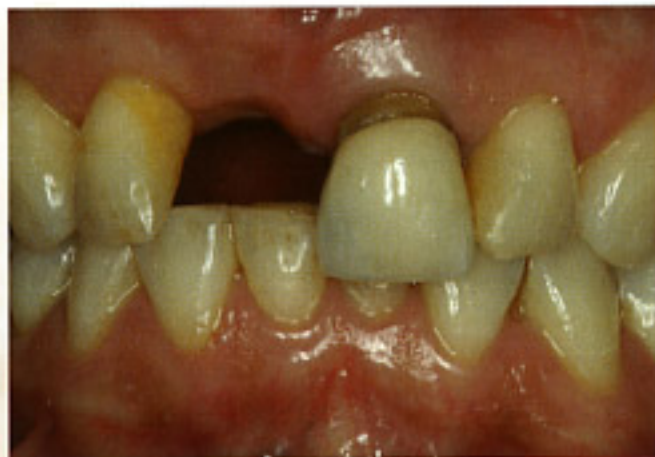

Fig. 28 Periodontal surgery to prepare the gingival line prior to re-entry at site 11.

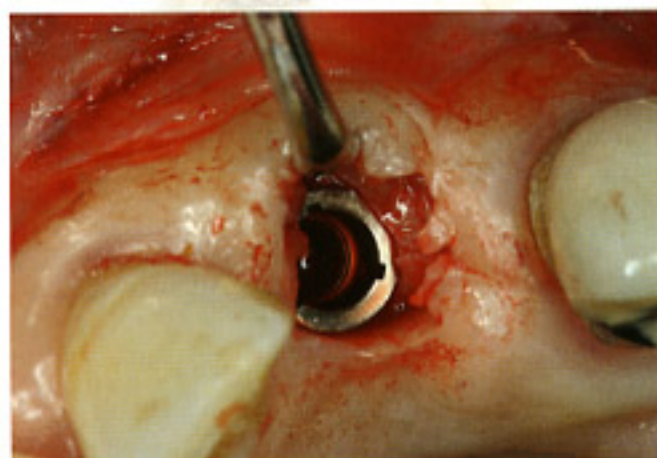


Fig. 29 Crescent-shaped incision.

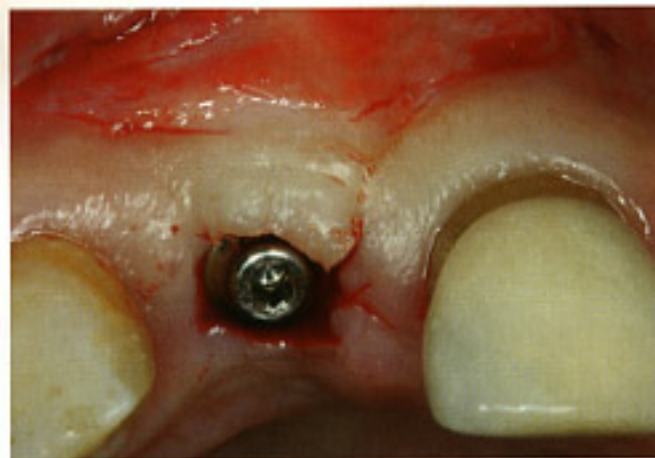


Fig. 30 Vestibuloplasty and bottleneck healing cap.

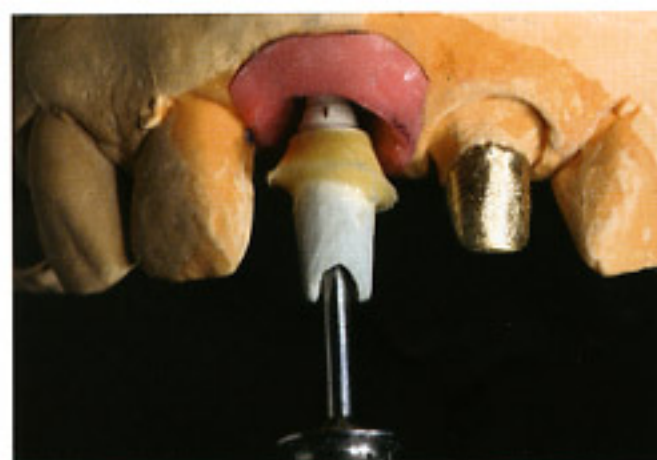

Fig. 31 Excellent volume gain of the peri-implant tissues, allowing the dental technician to reduce the gingival mask for creating the ideal emergence profile at site 11.

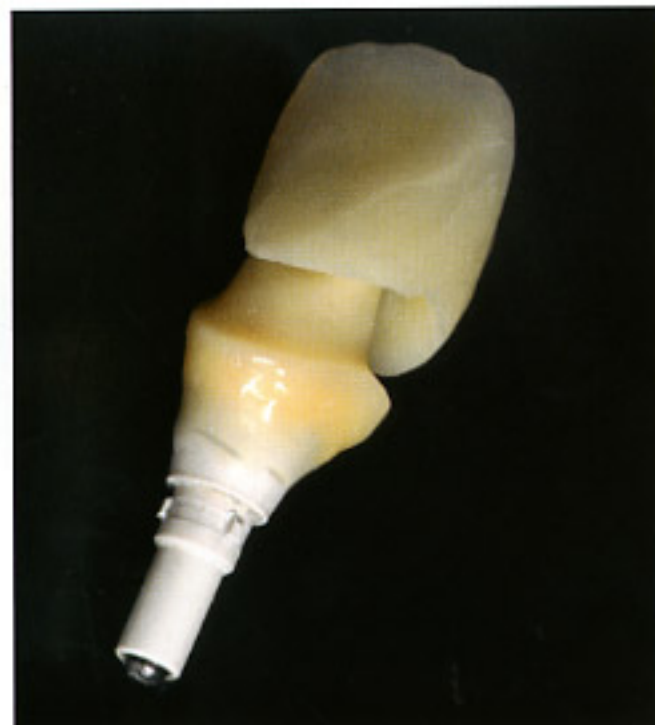

Fig. 32  
Reduced-diameter PEEK abutment  
and provisional cemented crown.